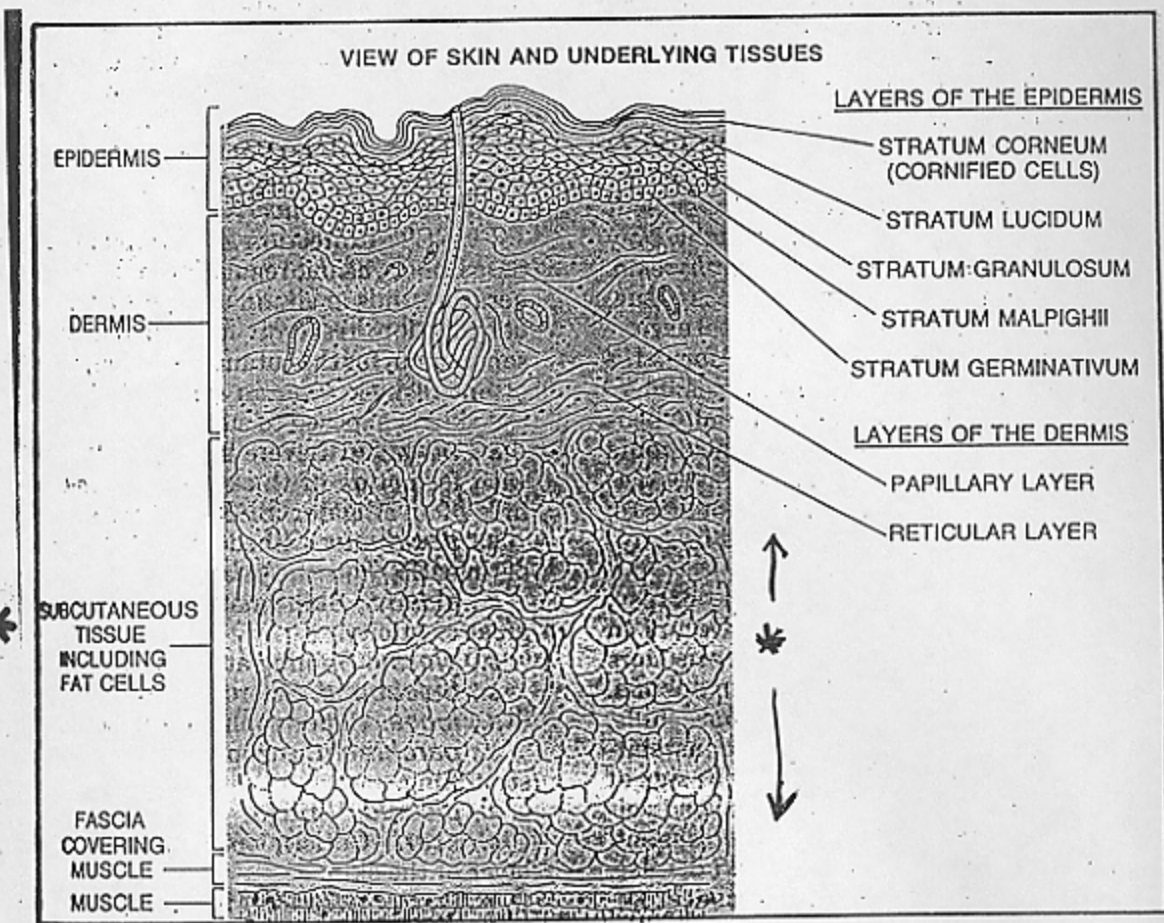


Handout 1
"Subcutaneous Mycoses"
and Fissures



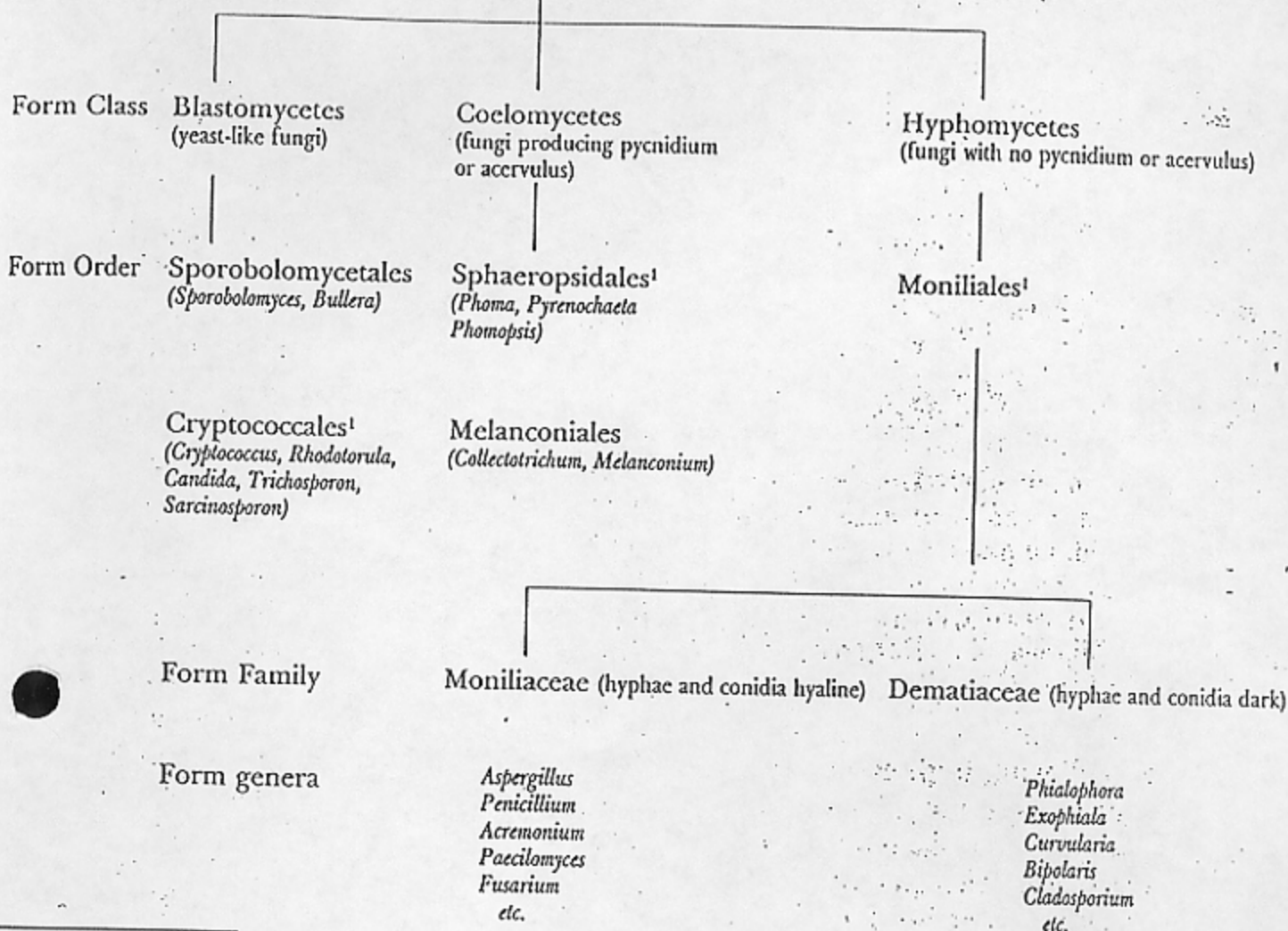
* subcutaneous
+ connective tissues

1. mucous
2. fibrous
areolar, white fibrous,
yellow fibrous, elastic
3. reticular
4. adipose (fat)

104a3

The Fungi

Deuteromycota (Fungi Imperfecti)



From Kwon Chung & Bennett
pg 27, Figure 9.18

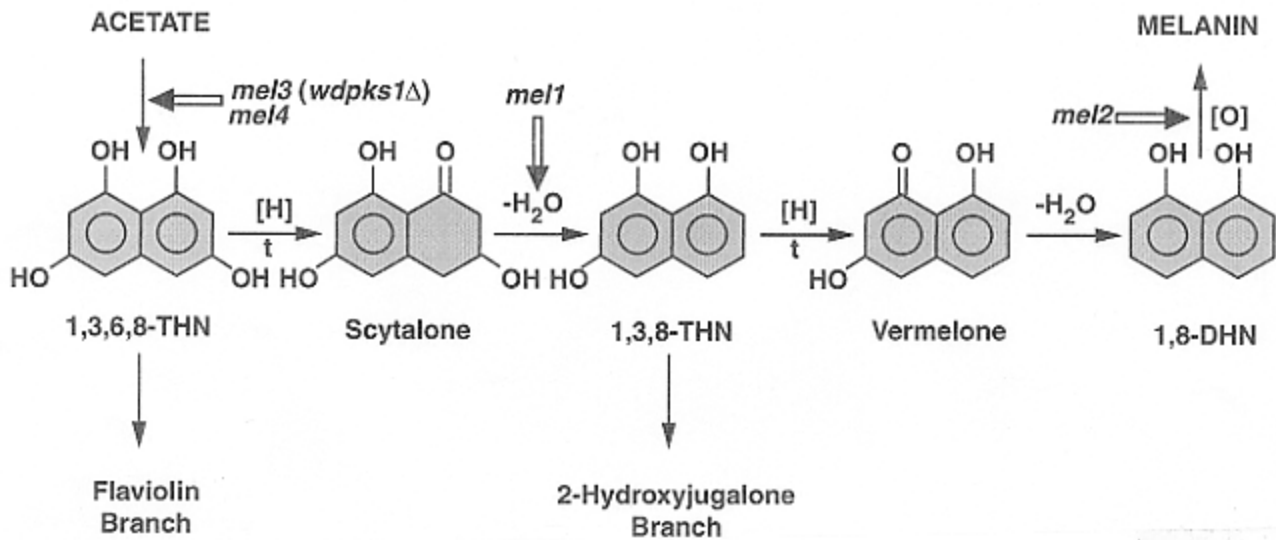


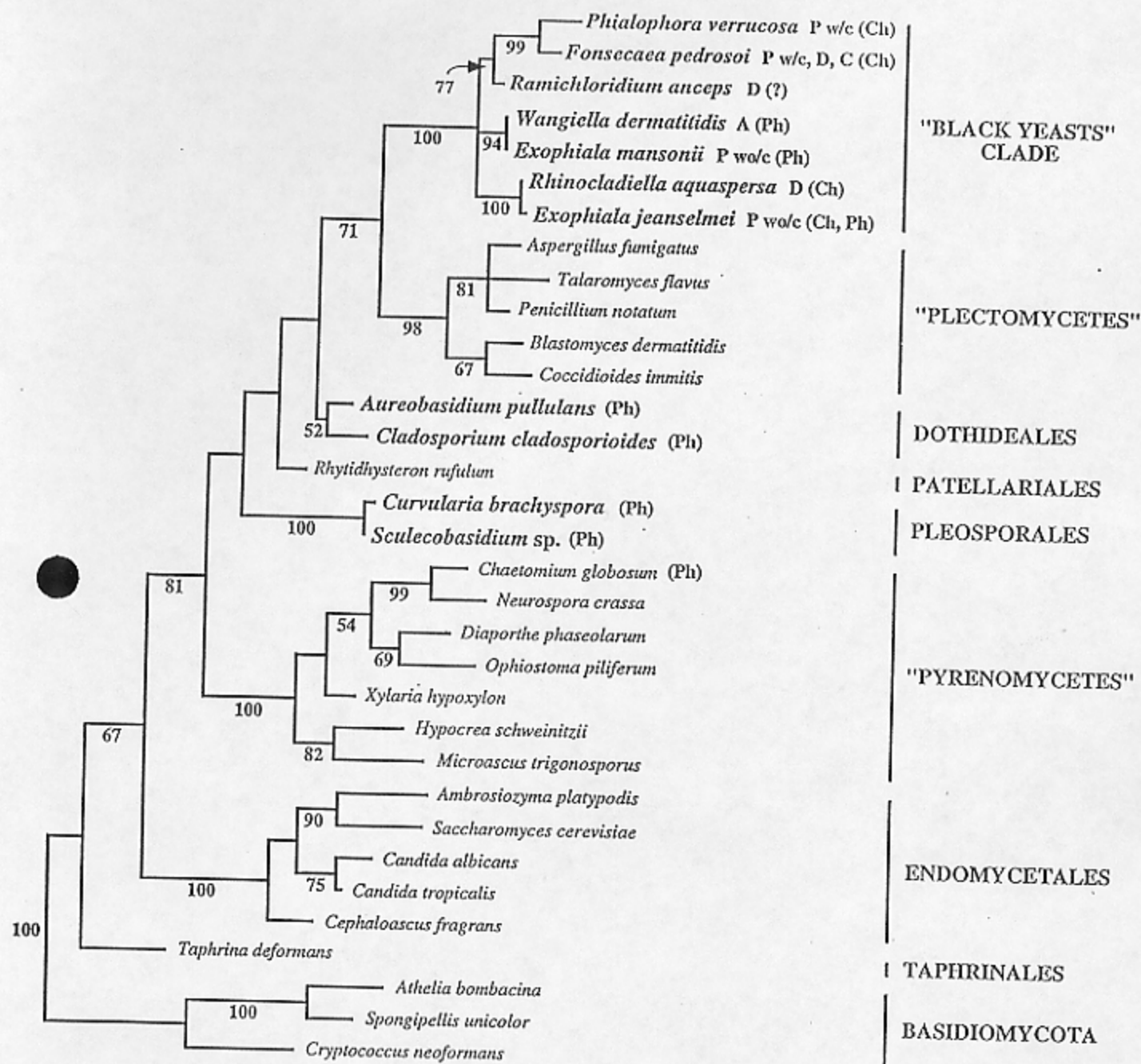
Figure 2. The pentaketide melanin biosynthetic pathway of *W. dermatitidis*. The pathway is shown without details of its major branches. The arrows point to locations of known lesions in *mel1*, *mel2*, *mel3 (wdpks1Δ)* and *mel4* strains. Other abbreviations are as follows: 1,3,6,8-THN, 1,3,6,8-tetrahydroxynaphthalene; 1,3,8-THN, 1,3,8-trihydroxynaphthalene; 1,8-DHN, 1,8-dihydroxynaphthalene; t, sites of tricyclazole inhibition; [H], reduction reaction; [-H₂O], dehydration reaction; [O], oxidation reaction. Modified from Geis et al., 1984.

TABLE 9-1. Characteristics of the Agents of Chromoblastomycosis and Phaeohyphomycosis

Species	Dermo-tropic	Neuro-tropic	Growth at 37°C	Gelatin	Primary Culture- Yeast	Growth Rate	Conidia Formation
<i>Fonsecaea pedrosoi</i>	+	±	+	-	-	Slow	<i>Cladosporium</i> primarily in short chains or, less commonly, from tips and sides of conidiophore; rarely from phialides. <i>Rhinocladiella</i> type conidiation often predominates.
<i>F. compacta</i>	+	-	+	-	-	Slow	Same as above, but <i>Cladosporium</i> conidial heads reduced and compact
<i>Wangiella dermatitidis</i>	+	+	+	-	+	Slow	Yeast forms early; abstrictions from tip and sides of conidiophores; semiendogenously from elongate phialides, also from peg-like phialides; grows at 40°C
<i>Phialophora verrucosa</i>	+	±	+	-	-	Slow	<i>Phialophora</i> type from flaring cups on flask-shaped phialides; other conidiation types rare or absent
<i>P. richardsiae</i>	+	-	+	-	-	Rapid	Phialoconidia semiendogenously; long phialides with saucer-shaped lips or collarettes
<i>Exophiala jeanselmei</i>	+	-	±	±	+	Slow	Yeast at first; abstrictions from sides and tips; semiendogenously from elongate annellides; no growth at 40°C
<i>E. spinifera</i>	+	-	±	-	+	Slow	Abstrictions from tips, sides, and along mycelium; conidiophores spikelike, not flared; bears conidia semiendogenously
<i>Cladosporium carrionii</i>	+	-	±	-	-	Slow	Long chains of conidia from branched conidiophore only; acropetalous; phialides on some media
<i>Xylohypha bantiana</i>	±	+	+	-	-	Slow	Similar to above, differentiation by thermotolerance (43°C), neurotropism, irregular spore size, and sparsely branching conidial chains of 35 or more elliptical conidia
<i>C. species</i>	-	-	-	+	-	Rapid	Same as <i>C. carrionii</i> ; usually not thermotolerant or pathogenic for animals

* all of these are "constitutively" melanized (dematiaceous)

From Reppich text, on MUSEUM



from Spataro et al., J. Clin. Microbiol. 33(1995)1322-1326.

0.050

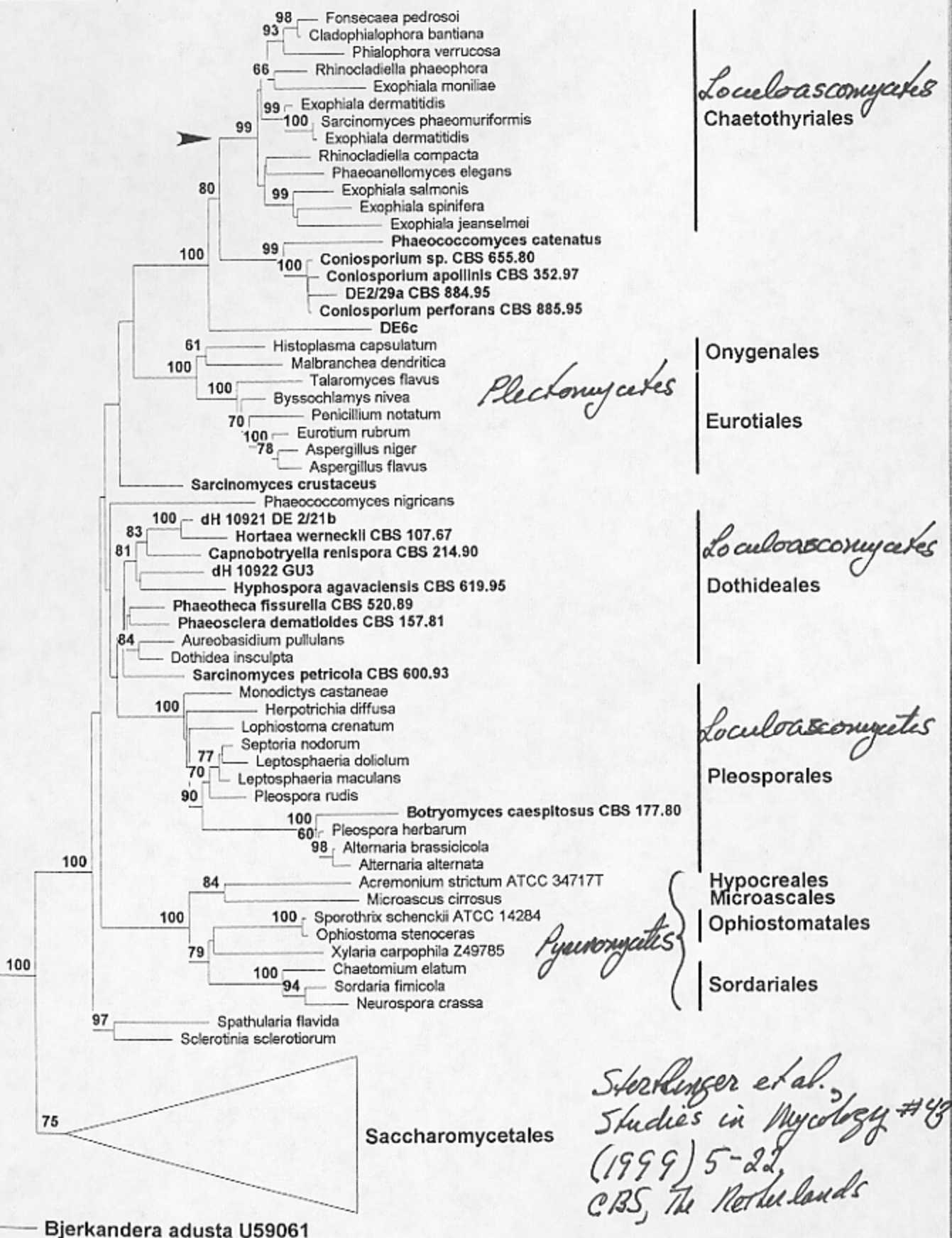
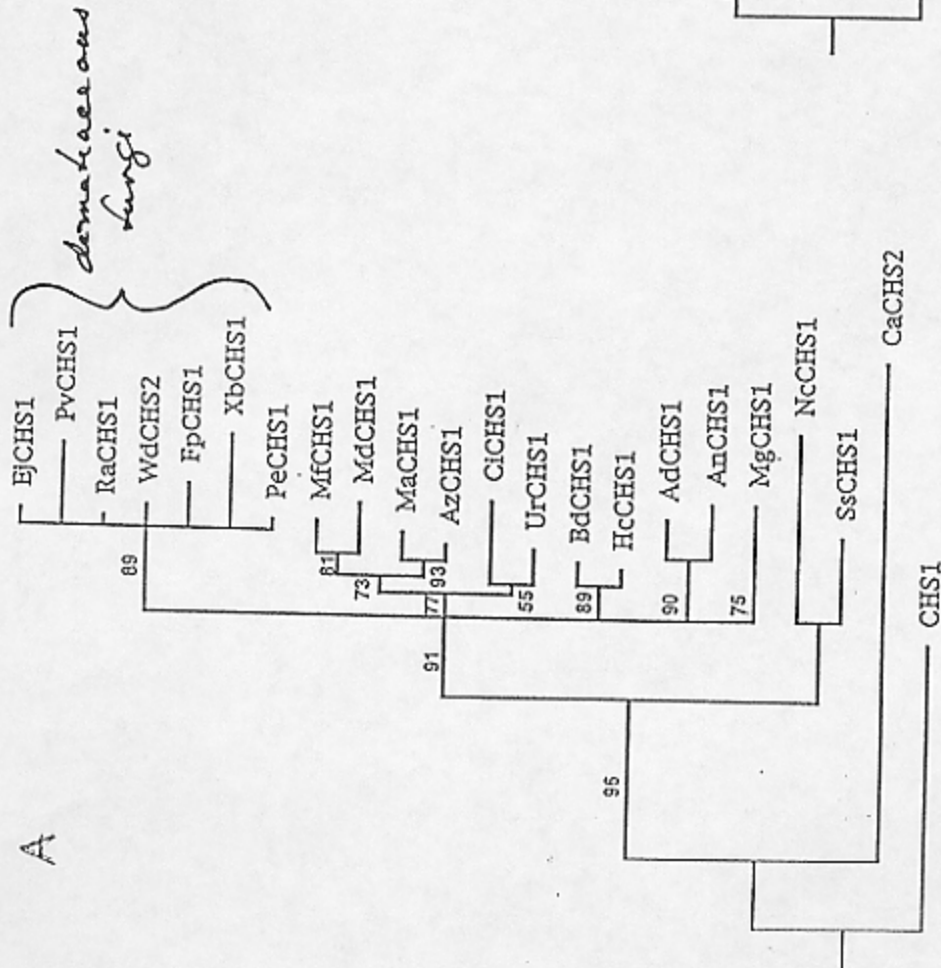


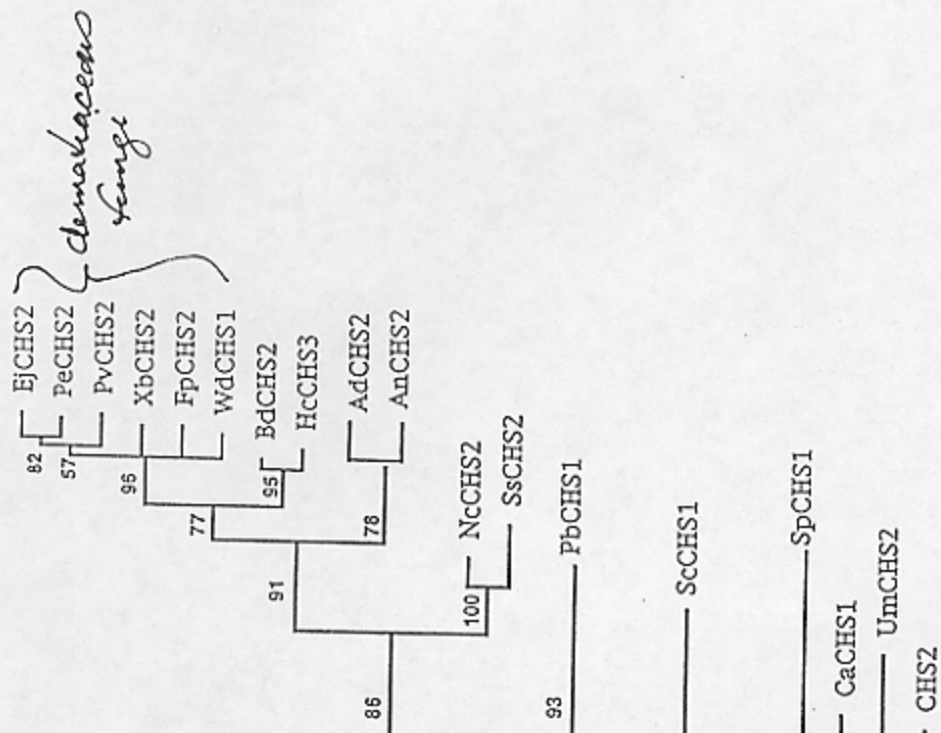
Fig. 4. Phylogenetic tree based on SSU sequences of 80 ascomycetes and one basidiomycete (as outgroup). The bootstrap values are generated from 500 bootstrap trees. The arrow indicates a hitherto unidentified plesiomorphic virulence factor.

A



dematiaceae fungi

B



dematiaceae fungi

phylogenies based on deduced amino acid
 sequences of chitin synthase gene
 fragments amplified by PCR.

From: Karuppayil, Pong, Mendoga, Lewis
 & Banerjee, 1996 JMMB 34:117-125

Table I. Clinical classification of phaeohyphomycosis and its principal etiologic agents

- A. Superficial phaeohyphomycosis
Infections confined to the stratum corneum with little or no tissue response. If hair is involved, the fungi grow superficially around the hair shaft with little damage to the hair.
1. Black piedra
 - a. *Piedraia hortae* •
 2. Tinea nigra
 - a. *Exophiala werneckii* •
(syn., *Cladosporium werneckii*)
 - b. *Stenella araguata*
(syn., *Cladosporium castellani*)
- B. Cutaneous and corneal phaeohyphomycosis
Keratinized tissues are invaded. Nonliving layers are generally involved, often exhibiting extensive tissue destruction.
1. Dermatomycoses
 - a. *Alternaria* sp.
 - b. *Scytalidium* state of *Hendersonula toruloidea*
 - c. *Taeniolella stilbospora*
 2. Mycotic keratitis
 - a. *Botryodiplodia theobromae*
 - b. *Curvularia geniculata*
 - c. *C. lunata*
 - d. *C. senegalensis*
 - e. *Drechslera rostrata*
 - f. *Exophiala jeanselmei* •
 - g. *Rhizoctonia* sp.
 - h. *Tetraploa* sp.
 3. Onychomycosis
 - a. *Botryodiplodia theobromae*
 - b. *Phyllosticta* sp.
 - c. *Scytalidium* state of *Hendersonula toruloidea*

Table I. Cont'd

- C. Subcutaneous phaeohyphomycosis
This is a heterogenous group of diseases that typically results from the traumatic implantation of the etiologic agents. The lesions usually remain localized with the formation of abscesses.
1. Agents
 - a. *Alternaria alternata*
 - b. *Cladosporium bantianum* •
(syn., *C. trichoides*)
 - c. *Drechslera spicifera*
 - d. *Exophiala jeanselmei* •
 - e. *E. moniliae*
 - f. *E. spinifera* •
 - g. *Phialophora bubakii*
 - h. *P. parasitica* •
 - i. *P. repens*
 - j. *P. richardsiae* •
 - k. *P. verrucosa* • ?
 - l. *Phoma* sp.
 - m. *Phoma hibernica*
 - n. *Scytalidium lignicola*
 - o. *Wangiella dermatitidis* •
- D. Systemic phaeohyphomycosis
The infections are often initiated in the lungs with subsequent dissemination to other organs. They may have a grave prognosis, especially infections involving the brain.
1. Agents
 - a. *Cladosporium bantianum* •
 - b. *C. cladosporioides*
 - c. *Curvularia geniculata*
 - d. *C. pallescens*
 - e. *Drechslera* sp.
 - f. *D. hawaiiensis*
 - g. *D. rostrata*
 - h. *D. spicifera*
 - i. *E. jeanselmei* •
 - j. *Mycelia Sterilia*
 - k. *Mycocentrospora acerina*
(syn., *Cercospora apii* sensu Emmons)
 - l. *Wangiella dermatitidis* •

From Rippon text - on nose

Developments in hyalohyphomycosis and phaeohyphomycosis

MATSUMOTO ET AL.

Wangiella dermatitidis infections as a paradigm of phaeohyphomycosis

W. dermatitidis (Kano) McGinnis is a phaeoid hyphomycete with a yeast form (synanamorph) that is an important aetiological agent of phaeohyphomycosis. The fungus was originally isolated in Japan from a human skin lesion in 1933, and it is encountered in clinical laboratories worldwide. Because of its broad spectrum of clinical features, as well as its confusing polymorphism *in vivo* and *in vitro*, *W. dermatitidis* has attracted the interests of both physicians and mycologists [55].

The nomenclature of infections caused by *W. dermatitidis* has been in a state of confusion [54]. Among phaeoid fungi, this fungus has an especially broad spectrum of clinical features, ranging in severity from superficial and mild, to deep seated and fatal. Another cause of controversy is the polymorphism of its fungal elements in tissue. They are observed as single or clustered spherical cells, catenulate cells comprising 2-5 cells, or septate mycelial fragments. In several cases, so called 'sclerotic cells', never exceeding one-septation, were recognized. Most of the early cases were reported under the name of chromoblastomycosis or chromomycosis, although clinically, they differed from the classic concept of chromoblastomycosis as originally conceived. Histologically, no thick-walled muriform cells with more than two septa, the essential tissue form of chromoblastomycosis, were observed [58].

We have critically reviewed the allegedly described cases of *W. dermatitidis* infections with available literature descriptions, clinical picture slides and histopathological materials, focusing especially on clinical features, patients' underlying conditions, sites of infection, hosts' histopathological reactions and fungal morphologies in tissue. As a result we confirmed 37 well documented cases of human *W. dermatitidis* infection [20]. Human infections caused by this mould can be separated into the following three groups: (i) superficial infections, such as keratomycosis and onychomycosis; (ii) cutaneous and subcutaneous phaeohyphomycosis; and (iii) visceral or systemic phaeohyphomycosis. The patients ranged in age from 10 to 79 years with a mean age of 38.9 years. Nineteen of the 37 patients were from Japan, 11 from the USA and two from Taiwan. It is noteworthy that most of the recent cases were reported from the USA and Europe. Nineteen patients had associated diseases or predisposing conditions. These included angina pectoris, chronic granulomatous disease, diabetes mellitus and intravenous heroin addiction. Superficial infections caused by *W. dermatitidis* comprised two cases of keratomycosis and one of onychomycosis; each should be recognized as corneal phaeohyphomycosis and ungual phaeohyphomycosis [22]. Infections caused by *W. dermatitidis* represent cases of cutaneous and subcutaneous phaeohyphomycosis. In 17 patients, the infections were limited to the skin and soft tissues. The face and neck were the most affected sites. Fine needle aspiration was recently established as an important first step in the diagnosis of these infections [22]. In 12 patients, fatal disseminated infection developed with organ involvement including the skin, lymph nodes, central nervous system and viscera. It should be noted that systemic and visceral infections caused by *W. dermatitidis*, without cutaneous or subcutaneous involvement, have been reported as phaeohyphomycosis of the brain,

endocardium, eye and lungs. The fatality rate was 32%, which is significantly higher when compared with the other aetiological agents of phaeohyphomycosis such as *E. jeanselmei*. Human infections caused by *W. dermatitidis* have been almost equally distributed among systemic involvement and cutaneous and subcutaneous infections. The most recently reported cases have further enlarged the broad spectrum of the clinical features of *W. dermatitidis* infections.

Infections caused by *W. dermatitidis* are notoriously resistant to treatment with antifungal drugs; their management is difficult and often frustrating. When small and localized cutaneous and subcutaneous lesions are amenable to surgical excision, the operation should be planned so that the lesion is removed with a margin of adjacent healthy tissue. When the infection is widespread, deep seated, visceral and disseminated, surgical treatment is impractical and chemotherapy with either amphotericin B or fluocytosine or combination therapy with both of these agents should be attempted. New antifungal agents, such as ketoconazole, fluconazole, itraconazole and terbinafine, show therapeutic promise. Clinical and experimental experience, however, will be needed before the most effective dosage and treatment schedules can be determined.

The tissue reaction in *W. dermatitidis* infections essentially presents as non-specific chronic and granulomatous inflammation, mainly consisting of lymphocytes, histiocytes, multinucleated giant cells and neutrophils. The intensity of host response, however, is variable, from a slight inflammatory reaction to severe reactions with necrosis. In several cases, cyst or abscess formation, commonly observed in cutaneous and subcutaneous phaeohyphomycosis caused by other phaeoid fungi, were recognized.

W. dermatitidis shows a wide range of fungal morphologies in tissues. They may be in the nature of dark-walled, short, septate, branched or unbranched hyphal elements, catenulate spherical cells (toruloid hyphae) as well as isolated spherical cells. The spherical cells occasionally resemble the muriform cells of chromoblastomycosis, but differ by having thinner walls and divide either by budding or septation in a single plane. In skin and subcutaneous tissues, *W. dermatitidis* tends to develop as spherical cells. In other organs, the mycelial form of the fungus is encountered more often. Where tissue reactions and fungal morphologies *in vivo* were concerned, in granulomatous lesions *W. dermatitidis* was present mainly in the form of spherical cells and, on other occasions, the fungus tended to develop as mycelium.

From clinical and histopathological points of view, the authors advocate that infections caused by *W. dermatitidis*, regardless of the fungal morphology in tissue or the host's response, are best referred to as phaeohyphomycosis. We also suggest that clinicians and mycologists worldwide should be alert to the occurrence of *W. dermatitidis* infections in their countries.

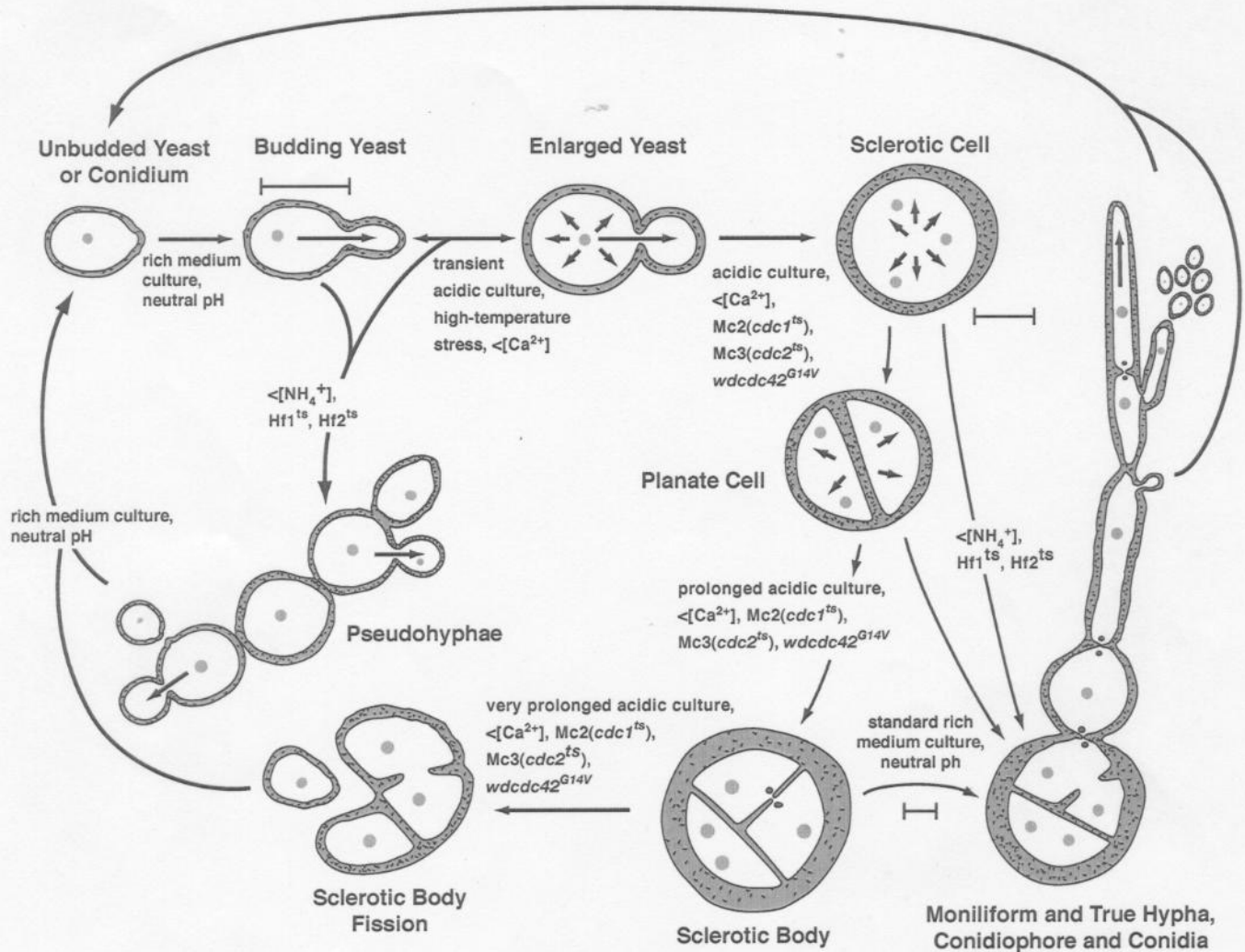


Figure 2. Schematic representation of the morphotypes of *W. dermatitidis* induced in vitro by various factors. Starting with a polarized budding yeast cell or conidium, some conditions induce pseudohyphal development because of the lack of yeast cell separation, while others induce the loss of polarity that lead to transient or prolonged isotropic development. The latter produces the morphotypes known as sclerotic cells, planate cells and sclerotic bodies. Return of the isotropic forms to conditions conducive to normal yeast growth usually leads to polarity reestablishments that result in moniliform and true hyphal outgrowths. Blastoconidia are then produced directly from hyphae and phialoconidia and annelloconidia from conidiophores, both of which can reestablish budding yeast populations. The morphotypes are not drawn to scale (note the differences in scale bars): the sclerotic cells and sclerotic bodies are often three to many times larger than mother yeast cells or conidia and usually have thicker walls enriched with both melanin and chitin. The ~ in the cell walls indicates chitin. (Modification of Figure 1, ref. Sz 16).

TABLE 3. Summary of clinical manifestations, diagnosis and treatment of selected agents of hyalohyphomycosis and phaeohyphomycosis

Organism	Common clinical manifestations	Methods for diagnosis	Treatment
<i>Bipolaris</i> species	Sinusitis, fungemia, cutaneous lesions, pulmonary lesions	Biopsy and culture of infected tissue, blood cultures	Depends upon host: Amphotericin B or itraconazole
<i>Xylohypha bantiana</i> (Syn. <i>Cladosporium bantianum</i>)	Isolated cerebral abscesses Disseminated infection, pneumonia	Biopsy and culture of infected tissue	Complete surgical resection of CNS lesions Amphotericin B? Flucytosine? Antifungal azole?
<i>H. dermatitidis</i>	Cerebral abscesses, endocarditis, Pulmonary lesions, cutaneous lesions, bone & joint infection	Biopsy and culture of infected tissue	Complete surgical resection of CNS lesions Amphotericin B? Flucytosine? Antifungal azole?
<i>Ochroconis gallopava</i> (Syn. <i>Dactylaria constricta</i> var. <i>gallopava</i>)	CNS infection including ventriculitis disseminated infection, pneumonia	Biopsy and culture of infected tissue	Complete surgical resection of CNS lesions Amphotericin B? Flucytosine? Antifungal azole?
<i>P. boydii</i>	Mycetoma, cerebral abscesses, pneumonia, endocarditis, endophthalmitis, disseminated infection	Biopsy and culture of infected tissue exoantigen, fluorescent antibody of tissue specimens	Surgical resection, where possible antifungal azole alone Combination of amphotericin GB and antifungal azole
<i>Scedosporium prolificans</i> (Syn. <i>S. inflatum</i>)	Musculoskeletal infection, disseminated infection	Biopsy and culture of infected tissue	Surgical resection, where possible Antifungal azole alone? Combination of amphotericin B and antifungal azole?
<i>Fusarium</i> species	Disseminated infection with maculomodular cutaneous lesions, fungemia, pulmonary infiltrates, and periungual infection	Biopsy and culture of infected tissue, blood cultures	Surgical resection, where possible Amphotericin B + flucytosine? Lipid formulation of amphotericin B? Investigational antifungal azoles

TABLE 5-4B. Mycotic Mycetoma

Species	Grain	Histology (H and E)	Colony and Microscopic Morphology	Physiologic Profile*						
				St	Gel	G	Gal	L	M	S
* <i>Pseudallescheria boydii</i>	White, soft, oval to lobed, <2 mm	Hyaline hyphae, 5 µm; huge swollen cells, <20 µm; no cement; red border, pink periphery	Rapid-growing; fluffy, mouse-fur gray; large 7-µm; unicellular conidia on simple conidiophore; black cleistothecia; 30-37°C; also synnemata in <i>Graphium</i> state	0	+	+	V	0	0	V
<i>Madurella grisea</i>	Black, soft to firm, oval to lobed, <1 mm	Little dark cement in edge; polygonal cells in periphery; center hyaline mycelium	Very slow-growing; leathery, tan-gray, later downy; sterile pycnidia; diffusible pigment; 30°C	+	-	+	+	0	+	+
* <i>Madurella mycetomatis</i>	Black, firm to brittle, oval to lobed, <2 mm	1. Compact type with brown-staining cement 2. Vesicular type with brown cement only at edge; swollen cells, <15 µm; center hyaline mycelium	Very slow growing; downy, velvety, smooth or ridged; cream-apricot to ochre; diffusible brown pigment; black sclerotia, <2 mm; rare conidia, phialides; 37°C	+	±	+	+	+	+	0
<i>Pyrenochaeta romeroi</i>	Same	Same grains without vesicles	Hyalin and brown hyphae. Pycnidioconidia in pycnidia	+	±	+	+	0	+	+
<i>Acremonium kilense</i>	White, soft, irregular, <1.5 mm	No cement; hyaline hyphae, <4 µm; swollen cells, <12 µm	White glabrous colony, later downy; violet pigment diffusible; curved septate; conidia arranged as head on simple conidiophore; 30°C	0	±	+	+	0	+	+
* <i>Exophiala jeanselmei</i>	Black, soft, irregular to vermicular, of 0.2 to 0.3 mm	Helicoid to serpiginous; center often hollow; no cement; vesicular cells, <10 µm; brown hyphae	Slow-growing; leathery, black, moist, later velvety; reverse black; toruloid yeast cells, moniliform cells, long tubular phialides; 30°C	0	0	+	+	0	+	+
<i>Leptosphaeria senegalensis</i>	Black, soft, irregular, ~ 1 mm	Black, hyphae; cement in periphery; center hyaline	Rapid-growing; downy gray; reverse black, rare rose pigment, diffusible; black ascstroma; <300 µm; septate ascospores, 25 x 10 µm	+	?	+	+	V	+	+
<i>Noctuidina rosarii</i>	Brownish white, soft, <1 mm	Polyhedral with filaments embedded in cement peripherally. Some vesicles in center	Slow growing, flat, folded, compact, light grayish brown. No conidia. In poor media black ascstroma form.							

*St, starch; Gel, gelatin; G, glucosa; Gal, galactosa; L, lactose; M, maltose; S, sucrosa.

Grain's size 0.2 → 5mm

Black
grain



✓ *Madurella mycetomatis*: black, hard, brittle, cemented together, consistency of coal

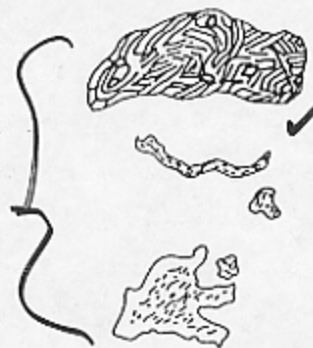✓ *Madurella mycetomatis*: vesicular, "open" grain, often with many large cyst-cells

Leptosphaeria senegalensis: black, soft to medium, irregular, cemented

Madurella grisea or *Pyrenochaeta romeroi*: soft, irregular, center hyaline, periphery black

✓ *Exophiala jeanselmei*: soft, open center, often filled with neutrophils, often wormlike and undulating, black

White
Grain



Scedosporium apiospermum

✓ *Pseudallescheria boydii*: very large, soft, lobulated white grains

Acremonium sp.: white, soft, small, lobulated, vermiform

Neotestudina rosatii: white, angulated mass, breaking into sections

Figure 5-11. Mycotic mycetoma: Morphology of grains.

Reppert pg 106

* Teleomorph/Holomorph

TABLE 5-4A. Taxonomy of the Agents of Eumycotic Mycetoma

Phylum: Dikaryomycota <i>Ascomycota</i>
Subphylum: Ascomycotina <i>Euascomycotina</i>
Class: Ascomycetes <i>Plectonycetes / Pyrenomyces?</i>
Series: unitunicatae-inoperculatae
Order: Sphaeriales <i>Microascales</i>
Family: Microascaceae (Melanosporaceae)
<i>Pseudallescheria boydii</i> ⁶⁸
(<i>Scedosporium apiospermum</i>)*
Series: Prototunicatae
Order: Eurotiales
Family: Eurotiacea
<i>Emmericella nidulans (Aspergillus nidulans)</i> ⁶³
Series: Bitunicatae
Order: Dothideales
Family: Pleosporaceae
<i>Leptosphaeria senegalensis</i> ³⁵
<i>Leptosphaeria tompkinsii</i> ⁸⁶
<i>Cochiobolus geniculatus</i> ^{13, 20, 33}
(<i>Curvularia geniculata</i> ³³)
<i>Conchiobolus specifer</i> ⁷⁵
Family: Testudinaceae
<i>Neotestudina rosatii</i> ⁸⁸
Anamorph genera of Dikaryomycota
Form Class: Hyphomycetes
Form Order: Moniliales
<i>Acremonium falciforme</i> ²⁷
<i>Acremonium killense</i> ^{44, 94}
<i>Acremonium recifei</i> ⁴⁴
<i>Curvularia lunata</i> ⁶³
<i>Corynespora cassicola</i> ⁶³
<i>Exophiala jeanselmei</i> ⁹³
<i>Exserohilum rostratum</i> ⁷⁹
<i>Fusarium moniliforme</i> ⁴⁸
<i>Fusarium solani</i> ⁴⁸
<i>Fusarium oxysporum</i> ⁴⁸
<i>Madurella grisea</i> ⁶⁵
<i>Madurella mycetomatis</i> ⁶⁵
Form Class: Coelomycetes
Form Order: Sphaeropsidales
<i>Plenodomus avramii</i> ¹⁸
<i>Pseudochaetosphaeronema larense</i> ^{15, 16, 80}
<i>Pyrenochaeta mackinnonii</i> ¹⁴
<i>Pyrenochaeta romeroi</i> ^{4, 17, 32}

White grains

Black grains

Form Families: Moniliales, Dematiaceae

*Anamorph genera are given in parentheses. 120

TABLE 5-48. Mycotic Mycetoma

Species	Grain	Histology (H and E)	Colony and Microscopic Morphology	Physiologic Profile*						
				St	Gel	G	Gal	L	M	S
* <i>Pseudallescheria boydii</i>	White, soft, oval to lobed, <2 mm	Hyaline hyphae, 5µm; huge swollen cells, <20 µm; no cement; red border, pink periphery	Rapid-growing; fluffy, mouse-fur gray; large 7-µm; unicellular conidia on simple conidiophore; black cleistothecia; 30-37°C; also synnemata in <i>Graphium</i> state	0	+	+	V	0	0	V
<i>Madurella grisea</i>	Black, soft to firm, oval to lobed, <1 mm	Little dark cement in edge; polygonal cells in periphery; center hyaline mycelium	Very slow-growing; leathery, tan-gray, later downy; sterile pycnidia; diffusible pigment; 30°C	+	-	+	+	0	+	+
* <i>Madurella mycetomatis</i>	Black, firm to brittle, oval to lobed, <2 mm	1. Compact type with brown-staining cement 2. Vesicular type with brown cement only at edge; swollen cells, <15 µm; center hyaline mycelium	Very slow growing; downy, velvety, smooth or ridged; cream-apical to ochre; diffusible brown pigment; black sclerotia, <2 mm; rare conidia, phialides; 37°C	+	=	+	+	+	+	0
<i>Pyrenochaeta romeri</i>	Some	Some grains without vesicles	Hyalin and brown hyphae. Pycnidia in pycnidia	+	=	+	+	0	+	+
<i>Acremonium kilense</i>	White, soft, irregular, <1.5 mm	No cement; hyaline hyphae, <4 µm; swollen cells, <12 µm	White glabrous colony, later downy; violet pigment diffusible; curved septate; conidia arranged as head on simple conidiophore; 30°C	0	=	+	+	0	+	+
* <i>Exophiala jeanselmei</i>	Black, soft, irregular to vermicular, of 0.2 to 0.3 mm	Helicoid to serpiginous; center often hollow; no cement; vesicular cells, <10 µm; brown hyphae	Slow-growing; leathery, black, moist, later velvety; reverse black; toruloid yeast cells, moniform cells, long tubular phialides; 30°C	0	0	+	+	0	+	+
<i>Leptosphaeria senegalensis</i>	Black, soft, irregular, ~ 1 mm	Black, hyphae; cement in periphery; center hyaline	Rapid-growing; downy gray; reverse black, rare rose pigment, diffusible; black ascostroma; <300 µm; septate ascospores, 25 x 10 µm	+	?	+	+	V	+	+
<i>Neofusarium rosali</i>	Brownish white, soft, <1 mm	Polyhedral with filaments embedded in cement peripherally. Some vesicles in center	Slow growing, flat, folded, compact, light grayish brown. No conidia. In poor media black ascostroma form.							

*St, starch; Gel, gelatin; G, glucose; Gal, galactose; L, lactose; M, maltose; S, sucrose.

* teleomorph of *Scedosporium apiospermum*

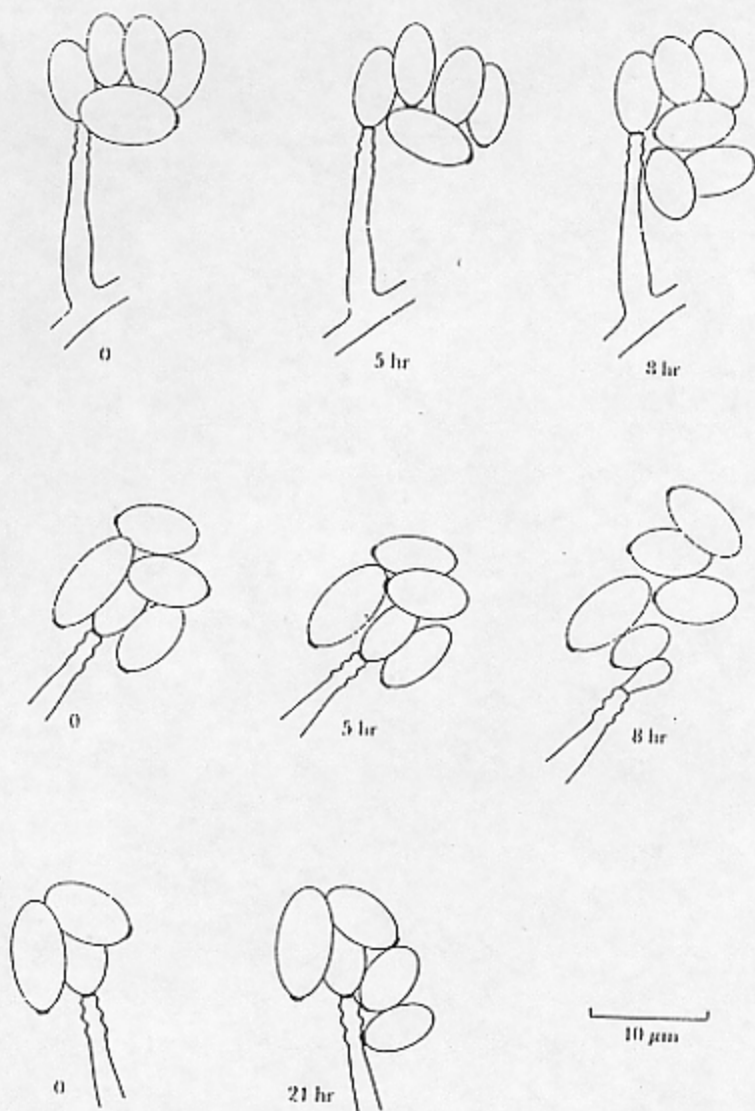


Figure 24-10. Conidiation of *P. boydii*. Camera lucida drawings of conidial development, showing sequential production of conidia in three conidiogenous cells at 28°C. The conidia accumulated as a wet mass near the apex of the conidiogenous anellide." (Courtesy of C. K. Campbell and M. D. Smith)

P. boydii
anulloconidogenesis

122

TABLE II
General Profiles of Clinical Cases of Infection by *Scedosporium inflatum*

Case number	History and predisposing factors	Clinical presentation	Therapy employed*	Outcome of infection
1	Parenteral trauma	Septic arthritis (knee)	Mic, Keto, Flu, AmB	Amputation; cleared
2	Parenteral trauma	Septic arthritis (knee)	Mic, Keto, AmB, and debridement	Cleared
3	Tibial fracture	Septic arthritis (knee)	Debridement, AmB	Cleared
4	Parenteral trauma	Septic arthritis (knee)	Debridement, AmB, Keto, and Mic	Cleared
5	Parenteral trauma	Osteomyelitis	Debridement	Cleared
6	Parenteral trauma	Osteomyelitis	Debridement, AmB, Keto	Cleared
7	Multiple fractures and trauma	Osteomyelitis and cellulitis	Debridement, AmB, Keto	Cleared
8	Scleroderma/skin ulcers	Gangrenous skin ulcers	Debridement	Cleared
9	IV drug abuse	Septic arthritis (hip)	Drainage, AmB, 5-FC	Cleared
10	Fever, chronic cough	Lung infection	Bronchoscopy (2x)	Cleared
11	Kidney transplant	Peritonitis	AmB, Mic	Died

Adapted from Wilson et al.¹⁵

*Mic, miconazole; Keto, ketoconazole; Flu, fluconazole; AmB, amphotericin B.

Pseudallescheriasis

TABLE I
Reported Infections Caused by *Pseudallescheria boydii*
(*Scedosporium apiospermum*)

Type of infection	Number of cases reported	Outcome of infection			
		Resolved	Death ^a	Persistent	Unknown
Pulmonary					
colonization	51	26	1 ^b (2.0)	1	23
fungoma	21	14	5 ^c (23.8)	—	2
invasive/pneumonia					
without dissemination	6	5	—	1	—
with dissemination	18	2	16 (88.9)	—	—
unspecified ^d	19	3	6 (31.6)	2	8
Central nervous system					
meningitis	7	1	5 (71.4)	—	1
brain abscess	10	5	5 (50.0)	—	—
Sinusitis	13	8	4 (30.8)	1	—
Endocarditis	5	1	4 (80.0)	—	—
Miscellaneous					
arthritis/osteomyelitis	20	17	—	1	2
keratitis	14	12	—	—	2
wound/soft tissue	13 ^e	10	—	1	2
endophthalmitis	6 ^f	3	2 (50.0)	—	—
optical orbit	2	2	—	—	—
Totals	205	109	48 (23.4)	7	40

Note: The data in this table were obtained from references cited in Rippon¹ and in Elder and Roberts² as well as from other documented case reports published in English language journals.^{3-14,16-20,22} Data from diverse reports of otomycosis are not included.

^aThe number in parentheses represents the number of deaths as a percentage of the number of infections reported.

^bNine deaths unrelated to colonization by *P. boydii* are not included.

^cTwo additional deaths caused by subsequent *Aspergillus* infection are not included.

^dThis category includes those case reports of colonization or fungoma in which data regarding the type of lesion is unclear or missing.

^eThis sum includes a single case of chronic prostatitis.

^fOne patient developed endophthalmitis subsequent to successful recovery from *Pseudallescheria* pneumonia. This individual is counted twice in this table.