

Students got respiratory disease after Acapulco vacations

Associated Press

ATLANTA — At least 100 college students nationwide have contracted a respiratory disease while on spring break in the Mexican resort city of Acapulco, federal health officials reported Friday.

All the students spent time at Acapulco's Calinda Beach Hotel and reported getting sick about 10 days after returning home. Centers for Disease Control officials believe that the disease might be histoplasmosis, a fungal infection that typically is easily treatable.

"It's not real serious for healthy people with no underlying health problems," CDC spokeswoman Barbara Reynolds said. The illness isn't contagious.

Officials first noticed the outbreak at a Pennsylvania college and traced the source to Acapulco

after working with other college health clinics. Infected students have been found in several states.

The hotel is still open and is working with health officials to halt the disease. Symptoms include acute respiratory distress, fever and body aches.

A2 Thursday, May 29, 1997

Histoplasmosis

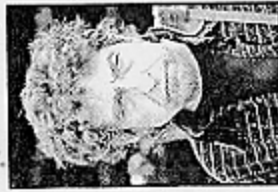NEWS

Dylan hospitalized with chest pains

By BRUCE WEBER

The New York Times

NEW YORK — Bob Dylan, whose bittersweet love songs and politically tinged folk anthems made him an emblem of the 1960s counterculture, canceled a European concert Wednesday, having checked into a hospital over the weekend suffering from severe chest pains.



Bob Dylan

According to a statement released Wednesday by an unnamed representative of Dylan's in England and made available to American news organizations by his record company, Columbia Records, the singer's condition was diagnosed as histoplasmosis. The statement said the condition was a potentially fatal infection that "creates a swelling of the sack which surrounds the heart."

However, according to the Merck Manual, a standard medical reference book, histoplasmosis is a fungal infection that may

cause acute pneumonia, but it is fatal "only in rare cases with massive infection."

Histoplasmosis is caused by fungal spores that are usually inhaled. The spores invade the lungs in airborne bird or bat droppings, said Dr. Peter Cohn, chief of cardiology at University Hospital at Stony Brook, N.Y.

"It's an infection of the heart valve, an infection of the pericardial sac," he said. "It's... hard to treat. Results with antibiotics are not great." Dr. Cohn said the disease is similar to tuberculosis and "can leave thick scar tissue around the heart."

Dylan, whose well-known songs include "Like a Rolling Stone," "The Times They Are A-Changin'" and "Just Like a Woman," turned 56 on Saturday. He was not available for comment Wednesday, and his whereabouts were not known.

The Bloomberg News Service reported that Dylan was in a New

York City hospital, but officials at two dozen local hospitals — including Columbia-Presbyterian Medical Center, New York University Medical Center and New York Hospital — all said Dylan had not been admitted.

Dylan's European tour was to have begun in Cork, Ireland, on June 1, and was to have included performances in England, Scotland and Switzerland. An American tour is scheduled for August, and the statement issued by Co-

lumbia said, "We are optimistic that we will be able to fulfill those touring commitments."

The youngest of Dylan's five children, Jakob, 27, lead singer of the rising group The Wallflowers, is in Amsterdam, Netherlands, on a European tour. His publicist said he has been told of his father's illness but apparently is making no plans to cancel the tour and return to New York.

This article includes material from Newsday.

Handout 9
Bio 329

2001
1997


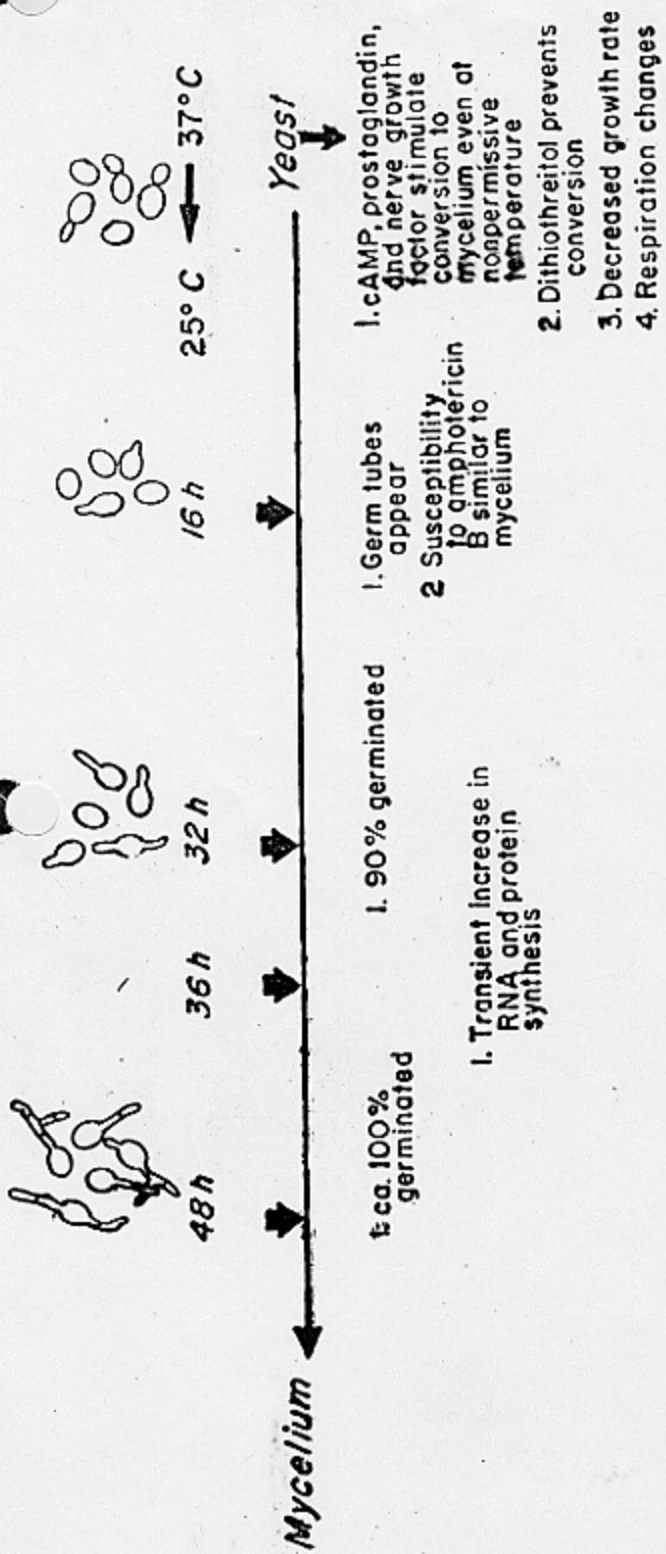


Figure 1 Model for the sequences of events associated with yeast \rightarrow mycelium and mycelium \rightarrow yeast transitions in the Downs strain of *Emmonsiaella capsulatum*. (Courtesy of G. S. Kobayashi and G. Medoff.)

Thermal derepression precedes
in some nutritional influenza

Mycelium

25°C

Mausca Kobayashi

→ 37°C

Stage 1
(1-40h)

1' Induction of heat shock phenomenon*
1' uncoupling of oxid. phosphorylation
5' decline in intracellular ATP concentration
30' induction of *hap70* & *hap83* genes*
30' absence of measurable ATP
6-40h decrease in aa concentration and RNA & protein synthesis

4h cysteine reductase appears

6-40h decrease in cytochrome *cytochrome*
6-40h decrease in respiration

40h changes in cAMP concentration*

PCMS prevents cells from entering stage 2

Stage 2
(40-72h)

no cytochromes detectable
no respiration

cysteine induces shunt pathway*
requirement of -SH groups to proceed towards stage 3

Induction of *TUP 1* & *TUB 2* genes

Yeast

Stage 3
(>72h)

Increase in:
RNA & protein synthesis
cytochromes

Induction of
cysteine oxidase
TUP 1 & *TUB 2* and
YPS-3 genes (late stage 3)
changes in RNA polymerase

FIG. 9. Sequences of events associated with mycelium to yeast transition in the Downs strain of *H. capsulatum*. Events that are boxed in are related. Respiratory activity is indicated by the bold line. * These events also can be activated in either mycelia or yeast cells without inducing phase transition.

1396

- I. Benign infection.
 - A. Usual dose: Endemic histoplasmosis
 - 1. Endemic subclinical disease: "Skin converters"
 - 2. Endemic symptomatic disease: Summer sickness in children and "fungus flu" in adults
 - 3. Primary cutaneous disease
 - B. Heavy dose: Epidemic histoplasmosis
 - 1. Acute pulmonary histoplasmosis
 - a. Primary infection (symptoms in 10 to 18 days)
 - b. Reinfection (symptoms in 3 to 7 days)
 - 2. Acute disseminated histoplasmosis
- II. Opportunistic infection
 - A. Disseminating histoplasmosis (with time course of disease)
 - 1. Fulminant disease of children (2 to 10 weeks)
 - 2. Moderately chronic disease of adults (several months)
 - 3. Mildly chronic disease of adults (10 to 20 years)
 - 4. Fulminant disease of adults associated with immunosuppression and/or lymphomatous diseases (rapid but variable)
 - B. Chronic pulmonary histoplasmosis
 - 1. Colonization of preexisting or acquired structural anomalies
 - 2. Smoker's emphysema and "migrating flashes" on x-ray examination
 - 3. Cavitory histoplasmosis
- III. Aberrant fibrosis and hypersensitivity disease
 - A. Histoplasmoma
 - B. Mediastinal fibrosis
 - 1. Superior vena cava syndrome
 - 2. Bronchocentric granulomatosis